

Silver Diamine Fluoride 38% - Clinical Uses

Silver Diamine Fluoride is Appropriate For...

- Patients with high risk sites:
 - Exposed root surfaces
 - Furcations
 - Deep pits and fissures
 - Food traps
 - Sites sensitive to hot/cold
 - "Watch" spots
 - Hypoplastic Molars
- All cavity-active patients:
 - Class V decay
 - Incipient decay
 - Interproximal decay
 - Special needs patients
 - Decay close to the pulp
 - Elderly patients with secondary decay (multiple medications)

Primary Prevention

Silver diamine fluoride 38% is being used for primary prevention on high risk sites. Without discoloration, silver penetrates into and remains on the surface of healthy dentin and/or enamel, providing antimicrobial biofilm resistance. This is particularly valuable in furcations, food traps, root surfaces and newly erupted occlusal surfaces that are difficult to dry and isolate for sealants.

Interproximal Lesion Application - Super Floss® Technique

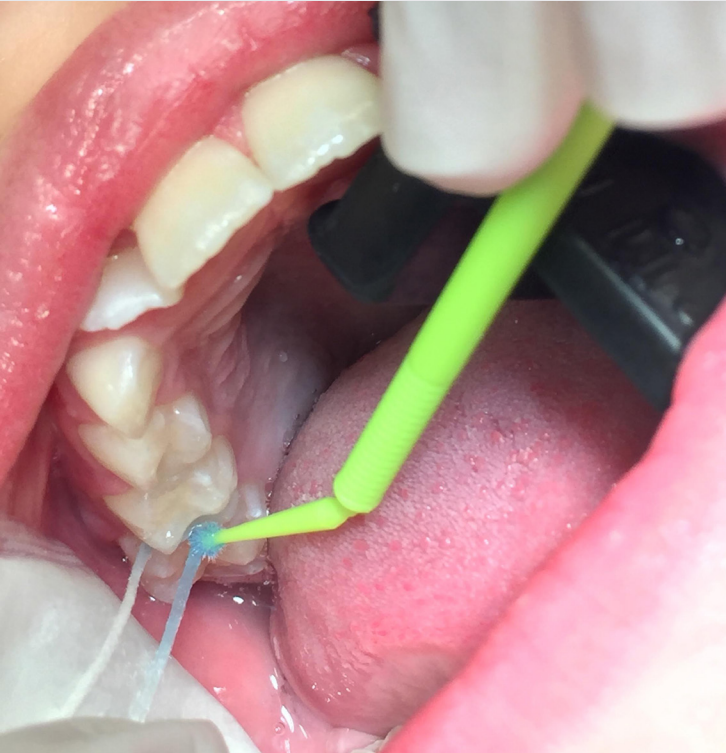

Photo courtesy of Dr. Jeanette MacLean

Arrest Decay at Restoration Margins

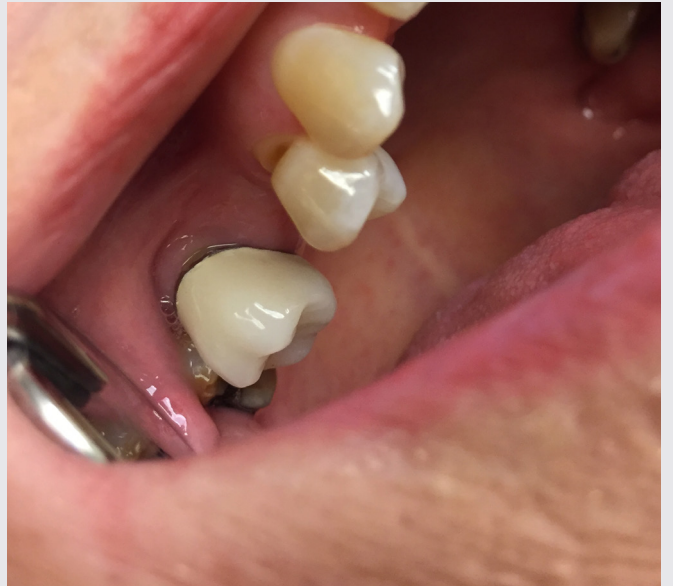

Photo courtesy of Dr. Jeanette MacLean

Micro-CT Scan of Dentinal Penetration of Silver Nanowires

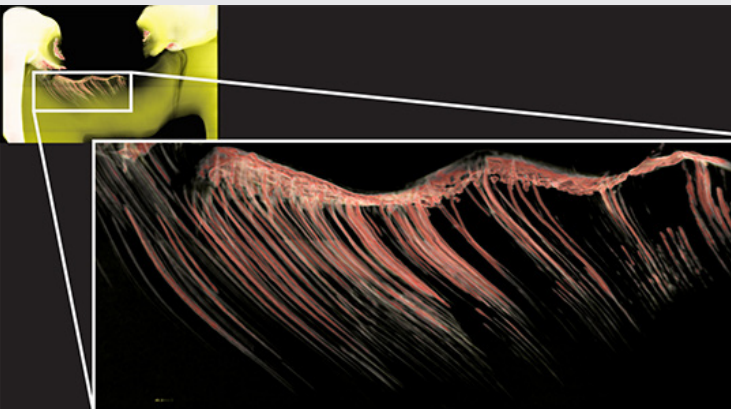


Photo courtesy of Drs. Jeremy Horst and Jong Seto

Nonsurgical Arrest of Incipient Caries

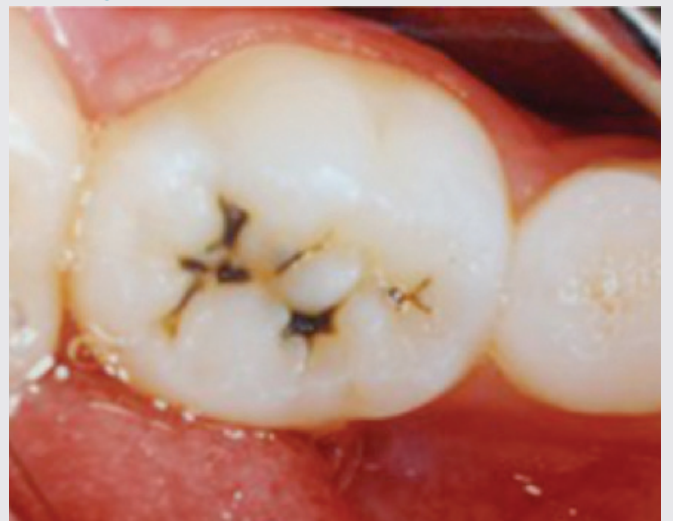

Photo courtesy of Dr. Steve Duffin

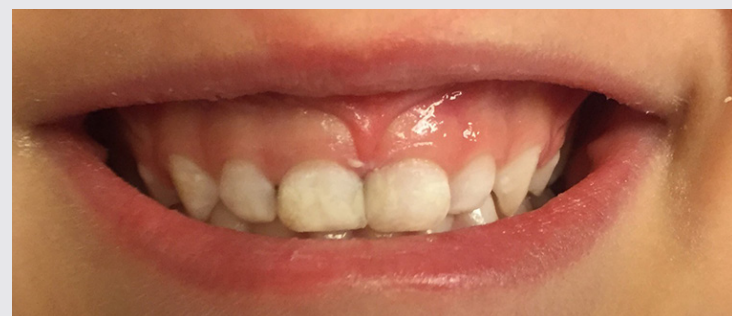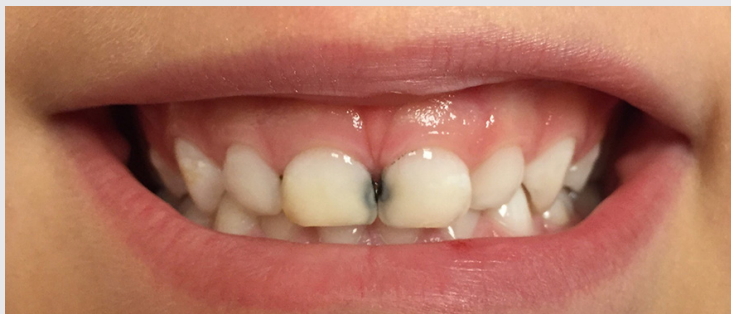Silver Diamine Fluoride 38% - SMART

Silver Modified Atraumatic Restorative Treatment (SMART) For Enhanced Esthetics

The before/after sets of images show teeth treated with silver diamine fluoride and then covered with glass ionomer. These materials can be placed in minutes without the need for drills, adhesives or instruments. SMART restorations will provide sufficient masking for most cases.

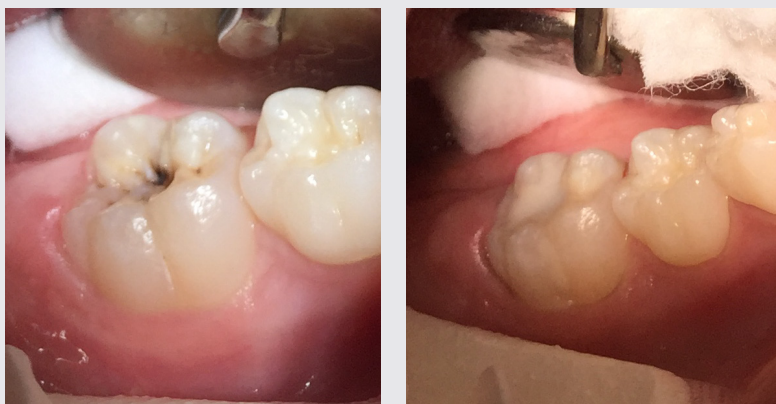In situations where esthetics are paramount, especially for permanent dentition, polish away discoloration along the margins, then cover the remaining discoloration with a "sandwich" of opaque glass ionomer followed by a composite material.

SMART with Nitrous Oxide, but No Local Anesthesia



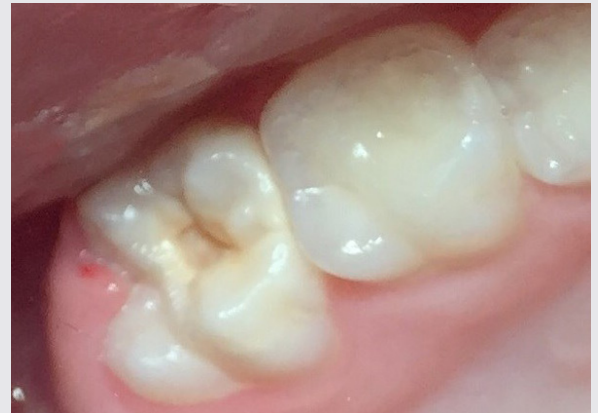Photos courtesy of Dr. Jeanette MacLean

SMART With No Tooth Structure Removal

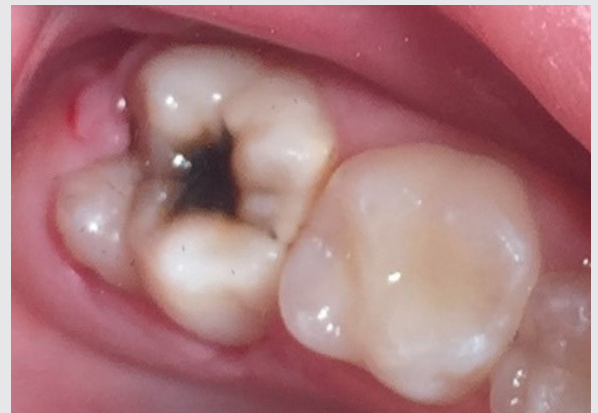

Photos courtesy of Dr. Jeanette MacLean

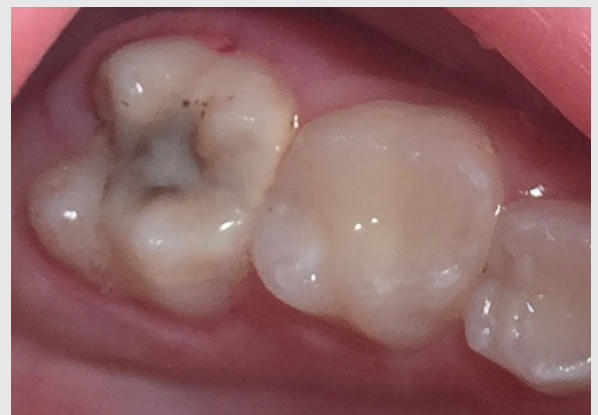Hypoplastic Molar SMART Application



Before



After SDF Application



Glass Ionomer Placed With No Tooth Structure Removal

Photos courtesy of Dr. Jeanette MacLean



Super Floss is a registered trademark of The Gillette Company Ltd.
© 2020 Elevate Oral Care • ELE498-013120